



Article/Artigo

Echocardiographic parameters associated with pulmonary congestion in Chagas cardiomyopathy

Parâmetros ecocardiográficos associados com a congestão pulmonar na miocardiopatia chagásica

Marselha Marques Barral¹, Maria Carmo Pereira Nunes^{1,3}, Marcia Melo Barbosa², Cid Sérgio Ferreira³, Wilson Campos Tavares Júnior³ and Manoel Otávio da Costa Rocha^{1,3}

ABSTRACT

Introduction: Discrepancy between the intensity of pulmonary congestion and the grade of cardiomegaly seems to be a common finding of Chagas cardiomyopathy, in spite of significant systolic dysfunction of the left ventricle. Its mechanism has not been established. The aim of this study was to investigate pulmonary congestion and to analyze if it correlated with Doppler echocardiographic parameters in patients with Chagas dilated cardiomyopathy. **Methods:** Fifty-five patients with positive serology tests for *Trypanosoma cruzi* and Chagas dilated cardiomyopathy were studied. Chest x-rays, Doppler echocardiogram and plasmatic brain natriuretic peptide levels were obtained in all patients. The degree of pulmonary venous vessels changes on chest x-ray was graded using a pulmonary congestion score, and then compared to Doppler echocardiographic parameters. **Results:** Mean age was 48.5 ± 11.2 years and 29% were women. The majority (95%) of patients were in NYHA functional class I and II. Mild pulmonary congestion by chest x-ray was found in 80% of the patients. In a multivariate analysis, left ventricular ejection fraction, right ventricular TEI index and the color M-mode velocity correlated with the degree of pulmonary congestion. **Conclusions:** Pulmonary venous changes on chest x-rays are frequent, but usually mild in patients with Chagas dilated cardiomyopathy. The degree of pulmonary congestion correlates with Doppler echocardiographic left and right ventricular dysfunction and with color M-mode velocity.

Key-words: Chagas disease. Echocardiography. Pulmonary congestion.

RESUMO

Introdução: Na miocardiopatia chagásica, é considerado haver uma menor intensidade de congestão pulmonar, mesmo na vigência de disfunção ventricular esquerda importante, não havendo ainda explicação definitiva para este fenômeno. O objetivo deste estudo foi de investigar a presença de congestão pulmonar na miocardiopatia chagásica e analisar se a intensidade da congestão esteve associada com parâmetros morfofuncionais ecocardiográficos de disfunção cardíaca. **Métodos:** Cinquenta e cinco pacientes com sorologia positiva para o *Trypanosoma cruzi* e portadores de miocardiopatia chagásica foram estudados. Todos os pacientes foram submetidos ao estudo radiológico do tórax, ecocardiograma e dosagem plasmática do peptídeo natriurético cerebral. O grau de congestão pulmonar foi quantificado através de um escore da congestão pulmonar, e então comparado com os parâmetros ecocardiográficos. **Resultados:** A idade média foi de 48.5 ± 1.2 anos e 29% eram mulheres. A maior (95%) parte dos pacientes encontrava-se na classe funcional I e II. Discreta congestão pulmonar à radiografia do tórax foi encontrada em 80% dos pacientes. Na análise multivariada, a fração de ejeção do ventrículo esquerdo, o índice de TEI do ventrículo direito e a velocidade ao color M mode foram as variáveis que mais estiveram associadas com o grau de congestão pulmonar. **Conclusões:** Nos pacientes com miocardiopatia chagásica, as alterações do fluxo venoso pulmonar foram frequentes, porém discretas. O grau de congestão pulmonar associou com parâmetros ecocardiográficos de disfunção ventricular esquerda e direita e com a velocidade do color M mode.

Palavras-chaves: Doença de Chagas. Ecocardiografia. Congestão pulmonar.

INTRODUCTION

Chagas disease is an important cause of death in several countries in Latin America, with great socioeconomic impact¹⁻³. The heart is the most frequently and severely involved organ in Chagas disease, and its impairment may result in death due to arrhythmia, heart failure or thromboembolic phenomena^{4,5}.

Chest x-ray is an important and inexpensive tool in the evaluation of patients with Chagas cardiomyopathy. An enlarged heart by this method indicates a poor prognosis⁶. However, pulmonary venous circulation by chest x-ray usually shows mild signs of pulmonary congestion, in spite of significant systolic dysfunction. In patients with Chagas cardiomyopathy, it is common to find a discrepancy between the intensity of pulmonary congestion and the grade of cardiomegaly, in spite of significant left ventricular systolic dysfunction⁷. The mechanism underlying the pulmonary congestion has not been established⁸.

Doppler echocardiography provides a variety of anatomic and functional information in Chagas dilated cardiomyopathy and represents one of the most important methods in the evaluation of these patients^{9,10}. Dilatation of the heart, with systolic and diastolic dysfunction by Doppler echocardiography are major findings in Chagas cardiomyopathy¹¹.

Therefore, the aim of this study was to investigate the degree of pulmonary congestion by chest x-ray and to evaluate its correlation with left ventricular function by Doppler echocardiography in patients with Chagas dilated cardiomyopathy.

METHODS

Fifty-five consecutive patients with Chagas dilated cardiomyopathy were enrolled. All patients came from a tertiary referring center for Chagas disease at the Federal University of Minas Gerais, in Belo Horizonte, Brazil.

1. Postgraduate Course of Infectious Diseases and Tropical Medicine, Federal University of Minas Gerais, Belo Horizonte, MG. 2. ECOCENTER, Socor Hospital, Belo Horizonte, MG. 3. Hospital das Clínicas, Federal University of Minas Gerais, Belo Horizonte, MG.

Address to: Dra. Marselha Marques Barral. R. Monsenhor Gustavo Freire 590/202, São Mateus, 36016-470 Juiz de Fora, MG, Brazil.

Phone: 55 32 3232-6103

e-mail: mbarral@terra.com.br

Received in 03/11/2009

Accepted in 08/02/2010

Following a pilot study with 10 patients, 52 patients were established as an adequate sample to conduct the present study.

Patients were included in the study if they had at least two positive serological tests for Chagas disease (indirect immunofluorescence, indirect hemagglutination and/or ELISA) and cardiomyopathy. Chagas dilated cardiomyopathy is characterized by the echocardiographic finding of a dilated left ventricle with impaired ventricular systolic function. Patients were selected if they had a left ventricular diastolic diameter/body surface area (BSA) ≥ 31 mm and left ventricular (LV) ejection fraction $< 55\%$ ¹². Patients were receiving optimized treatment for heart failure and inclusion was independent of drug regimen. Patients who had associated heart diseases or systemic arterial hypertension were excluded.

All patients underwent clinical examination and NYHA functional class was established. Medical therapy was individually adjusted according to a standardized treatment regimen. Chest x-rays, B-type natriuretic peptide (BNP) plasmatic levels, and Doppler echocardiograms were obtained on the same occasion in all patients. Chest x-ray was obtained in the postero-anterior and lateral positions. All films were acquired using the conventional technique of the Radiology Department of the University Teaching Hospital¹³. All radiological parameters were graded and the intensity of pulmonary venous vessels changes on chest x-ray was established (**Table 1**) using a previously described pulmonary congestion score (PCS)^{14,15}. Two independent observers simultaneously evaluated the chest X-rays and any discordance were solved by consensus. The inter observer reproducibility was analyzed.

Echocardiography

Images were acquired using a Sonos 5,500 (Hewlett-Packard Corporation, Palo Alto, CA) with 2.5-MHz to 3.5-MHz transducers. All recordings were performed by one investigator, who was blinded to the clinical evaluation of the patients. The echocardiographic techniques and calculations of different cardiac dimension and volumes were performed according to the recommendations of the American Society of Echocardiography. LV ejection fraction was calculated according to the modified Simpson's rule¹².

Quantitative evaluation of global right ventricular (RV) function was performed by the Doppler-derived index of myocardial performance (Tei index), as previously described¹⁶. RV morphology and function were evaluated qualitatively on multiple echocardiographic views¹².

The presence and degree of mitral and tricuspid regurgitation were evaluated by pulsed and continuous wave Doppler guided by color flow mapping¹⁷. Maximal velocity of the tricuspid regurgitation flow was obtained and systolic pulmonary pressure calculated¹⁸.

Diastolic function was assessed by pulsed-wave Doppler examination of mitral, pulmonary venous inflow and Doppler tissue imaging (systolic, E' and A' waves)^{19,20}. The ratio between peak early diastolic transmitral flow velocity (E) and E' was calculated. Color Doppler M-mode was also used to assess ventricular diastolic function²⁰. According to these Doppler parameters, four patterns of diastolic function were established: normal, and grades I (abnormal relaxation pattern), II (pseudonormal pattern) and III (restriction to filling) of diastolic dysfunction.

TABLE 1 - Pulmonary venous vessels of patients with Chagas dilated cardiomyopathy, seen using chest x-ray.

Pulmonary venous vessels distribution	Physiopathology	Estimated pulmonary venous pressure		Value
Normal	None	8-12mmHg		1
Equalization	Pulmonary venous hypertension	13- 15mmHg	Mild	2
			Moderate	3
			Severe	4
Inversion	Pulmonary venous hypertension	16-18mmHg	Mild	5
			Moderate	6
			Severe	7
Perihilar haze	Interstitial edema	> 18mmHg	Mild	+1*
			Moderate	+2*
			Severe	+3*
Subpleural thickening	Interstitial edema	> 18mmHg	Mild	+1*
			Moderate	+2*
			Severe	+3*
Peribronchial cuffing	Interstitial edema	> 18mmHg	Mild	+1*
			Moderate	+2*
			Severe	+3*
Pleural effusion	Interstitial edema	> 18mmHg	Mild	+1*
			Moderate	+2*
			Severe	+3*
Kerley lines	Interstitial edema	> 18mmHg	Mild	+1*
			Moderate	+2*
			Severe	+3*
Consolidation	Alveolar edema	> 25mmHg		11

*Value added to pulmonary venous vessels distribution grading on the corresponding chest x-ray film.

BNP levels

Venous blood samples were obtained by direct venous puncture on the same day of the echocardiogram. Serum NT-proBNP was determined with a sandwich immunoassay on an Elecsys 2010 (Roche diagnostics). The NT-proBNP method is considered precise, has a wide dynamic measuring range, is free from common interferences, and does not cross-react with BNP²¹.

Statistical analysis

Data were expressed as the mean value \pm standard deviation for continuous variables and absolute or relative frequencies for categorical variables. Inter-observer reproducibility was evaluated by the Kappa coefficient, considering satisfactory if near to 1.

Correlations between PCS and echocardiographic variables were assessed using linear regression analysis.

Multiple linear regression analysis was constructed to obtain the best regression model, with the PCS as the dependent variable and the echocardiographic parameters as the independent variables. The permanence of all variables in the final model was established when the significance level was < 0.05 . SPSS version 13 (SPSS Inc., Chicago, Illinois) was used for all analyses.

Ethical

The research protocol was approved by the Research Ethics Committee of the institution and a written informed consent was obtained from all patients.

RESULTS

A total of 55 patients were enrolled. The mean age was 48.5 ± 11.2 years and 29% were women. Twenty-five (46%) patients were in NYHA class I, 27 (49%) in class II, and only three (5%) in class III/IV. There was significant association between functional class and the degree of pulmonary congestion ($p=0.005$; $r=0.375$). The heart failure treatment was analyzed and didn't modified the grade of pulmonary congestion.

Chest x-ray was normal in 11 patients and showed some degree of pulmonary venous abnormalities in the remaining 44 (80%) patients. The radiological findings of pulmonary congestion are shown on **Table 2**. Mean value of lung congestion score was 4.22 ± 2.29 . The kappa coefficient was 0,58 to perihilar haze; 0,86 to presence of subpleural thickening; 0,78 to peribronchial cuffing; 1,0 to equalization, inversion, consolidation and pleural effusion.

Doppler echocardiographic parameters associated with the PCS are shown on **Table 3**. The mean LV ejection fraction was $36.7 \pm 10.5\%$ (median: 40%). LV ejection fraction correlated with the degree of pulmonary congestion ($r = -0.58$; $p=0.001$), as shown

TABLE 2 - Pulmonary congestion score.

Venous flow characteristics	Patients		Score
	n	%	
Normal	11	20.0	1
Mild equalization	6	10.9	2
Moderate equalization	4	7.3	3
Mild inversion	17	30.9	5
Moderate inversion	16	29.1	6
Severe inversion	1	1.8	7
Kerley lines	2	3.6	1
Mild subpleural thickening	5	9.1	1
Moderate subpleural thickening	1	1.8	2
Pleural effusion	2	3.6	1

on **Figure 1**. The PCS was also associated with systolic pulmonary artery pressure ($r=0.56$; $p=0.002$), as shown on **Figure 2**.

Various parameters used to evaluate diastolic function were associated with pulmonary congestion (**Table 3**). According to the established classification of diastolic dysfunction, six (10.9%) patients had normal diastolic function, 36 (65.5%) showed grade I of diastolic dysfunction, five (9.1%) grade II and eight (14.5%) grade III. The degree of diastolic dysfunction was also associated with the PCS ($p<0.001$). The mean E/E' ratio was 6.3 ± 2.8 and it did not correlate with pulmonary congestion.

Mitral regurgitation was mild in ten (18%) patients and moderate in five (9%). The degree of mitral regurgitation was also associated with PCS ($p=0.003$). BNP levels correlated with pulmonary

TABLE 3 - Doppler echocardiographic parameters associated with the pulmonary congestion score.

Variables	Mean \pm SD	R value	P value
LVd (mm)	62.45 ± 6.24	0.31	0.020
LVS (mm)	50.31 ± 7.33	0.34	0.010
LAd (mm)	42.64 ± 9.64	0.34	0.012
FS (%)	19.22 ± 5.71	-0.31	0.019
EF (%)	37.71 ± 10.52	-0.58	0.001
E wave (cm/s)	73.28 ± 26.21	0.33	0.014
A wave (cm/s)	66.73 ± 27.81	0.29	0.030
E/A	1.34 ± 0.88	0.41	0.002
DT (ms)	243.22 ± 72.68	-0.43	0.001
IVRT (ms)	106.22 ± 19.12	-0.38	0.004
dPVF (cm/s)	44.82 ± 18.66	0.28	0.036
E' wave (cm/s)	12.36 ± 3.79	0.26	0.058
E'/A'	0.89 ± 1.18	0.32	0.018
Color M-mode (cm/s)	35.52 ± 14.33	0.26	0.060
SPAP (mmHg)	32.98 ± 12.44	0.56	0.002
RV Tei index	0.38 ± 0.33	0.26	0.050
BNP (pg/ml)	1167.18 ± 1573.41	0.37	0.009

LVd: left ventricular diastolic diameter; LVS: left ventricular systolic diameter; LAd: diastolic diameter of the left atrium; EF: ejection fraction; FS: fractional shortening; E: early diastolic transmitral flow velocity; A: late transmitral flow velocity; E/A: ratio of early to late transmitral flow velocity; DT: deceleration time of the E wave; IVRT: isovolumic relaxation time; dPVF: diastolic component of pulmonary venous flow; E': early diastolic mitral annular velocity; A': late diastolic mitral annular velocity; E'/E': ratio of the early diastolic transmitral flow velocity to early diastolic mitral annular velocity; color M-mode: velocity slope of the color M-mode; SPAP: systolic pulmonary artery pressure; RV: right ventricle; BNP: brain natriuretic peptide.

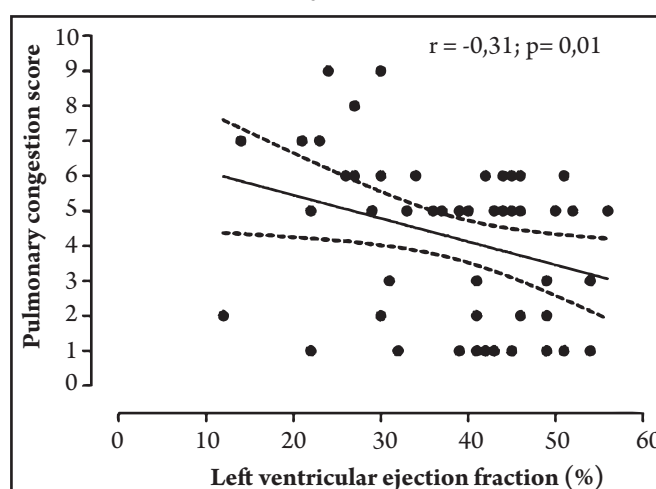


FIGURE 1 - Correlation between ejection fraction and the degree of pulmonary congestion.

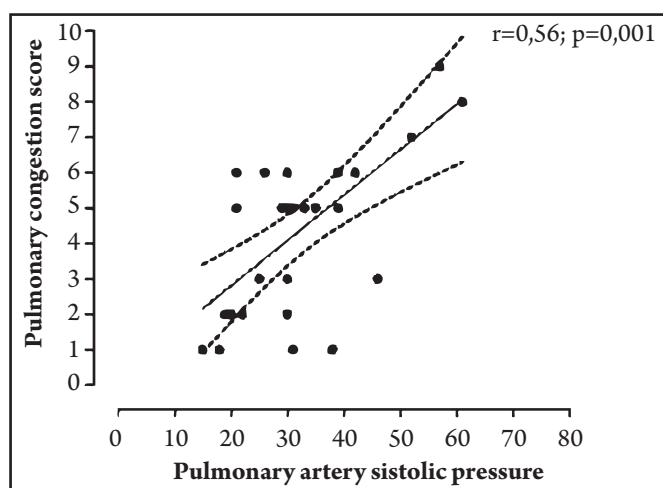


FIGURE 2 - Correlation between systolic pulmonary artery pressure and pulmonary congestion score.

congestion. However, when we included variables of LV systolic and diastolic function in the multivariate model, BNP levels were not predictive of pulmonary congestion.

In multivariate analysis, the echocardiographic variables that remained correlated with the PCS were LV ejection fraction, RV Tei index and color M-mode velocity. The final regression equation ($r = 0.580$) was: $PCS = 3.463 + 4.064 (RV \text{ Tei index}) + 0.051 (\text{color M-mode}) - 0.069 (LV \text{ ejection fraction})$

DISCUSSION

Chest x-ray is an important exam in dilated cardiomyopathy, providing noninvasive information about heart dimension and pulmonary vessels at low costs⁶. To the best of our knowledge, the present study is the first to correlate parameters of pulmonary congestion by chest X-ray with ventricular dysfunction by Doppler echocardiogram in patients with Chagas cardiomyopathy. Similar to other studies^{22,23}, PCS correlated with several prognostic parameters of heart failure, such as NYHA functional class, LV ejection fraction and RV dysfunction. Abnormalities of venous pulmonary pressure by chest x-ray have been compared to Doppler echocardiograms in elderly patients with systolic dysfunction. Radiological changes have been shown to present a sensitivity of 76% in detecting echocardiographic parameters of LV dysfunction²⁴.

It has been previously reported that in Chagas dilated cardiomyopathy, lungs usually do not show findings of severe pulmonary congestion. This is a peculiar aspect of this cardiomyopathy, which shows more congestion in the systemic circulation than in the pulmonary territory⁴. In the present study, some degree of pulmonary congestion was present in 80% of the chest x-rays and it was usually mild. The essential feature of LV dysfunction is an increase in left atrial pressure and pulmonary venous congestion leading to fluid flow across the pulmonary microvasculature²⁵. In fact, in our study, ejection fraction remained an important factor associated with pulmonary congestion.

Although left ventricular dysfunction was present, 20% of the chest x-rays did not show any signs of pulmonary congestion. This could be explained by the fact that, in the scenario of cardiac failure, venocapillary marks on chest x-ray do not necessarily correlate with capillary pulmonary pressure. The absence of interstitial or alveolar edema doesn't necessarily mean that capillary pressure is normal.

Our patients were in NYHA functional class I or II, so these results can not be extrapolated to the whole population of patients with Chagas cardiomyopathy.

Chagas cardiomyopathy is a chronic myocarditis of an inflammatory nature with a progressive fibrotic process affecting the myocardial of both ventricles. RV involvement may occur more often in Chagas cardiomyopathy than in other forms of dilated cardiomyopathy⁸. Moreover, chagasic patients with RV dysfunction present with more extensive left ventricular involvement due to the pathologic process, and have a poorer prognosis²⁶. In the present study, higher PCS was also observed when severe LV dysfunction was associated with RV dysfunction.

The Tei index is easily obtained and has been reported to be clinically useful in assessing global RV function¹⁶. Because the index has a wide numeric range, it may better assist in reflecting the various degrees of RV dysfunction. In the present study, we showed a correlation between a prolonged RV Tei index and pulmonary congestion, supporting the hypothesis that the clinical severity of RV dysfunction was associated with the impairment of LV function. Tei *et al*¹⁶ have shown that the index correlate with symptoms and survival in patients with primary pulmonary hypertension. A previous study from our group has shown the correlation of pulmonary artery pressure and RV dysfunction in Chagas cardiomyopathy²⁷. Lewis *et al* found the same correlation in patients with idiopathic cardiomyopathy²⁸.

Although the E/E' ratio has been shown to be associated with a pulmonary capillary wedge pressure in patients with depressed ejection fractions²⁹, in the present study, the E/E' ratio did not remain in the final regression model. This may be explained by the fact that most of our patients were clinically stable, and probably had lower LV filling pressures, as demonstrated by the lower values of E/E' ratio found in these patients.

The propagation velocity of the E wave, as assessed by color Doppler M-mode, has been demonstrated to be a measure of ventricular relaxation, which is essentially independent of preload. In the present study, color M-mode velocity emerged as an independent predictor of pulmonary congestion, after adjusting for LV ejection fraction and RV function. Similarly, Schwammenthal *et al*³⁰ found that an index derived of color M-mode velocity, E/Vp, was the best predictor of pulmonary congestion in a subgroup of patients who underwent cardiac catheterization.

In conclusion, pulmonary venous changes are frequent but usually mild in patients with Chagas cardiomyopathy. The degree of pulmonary congestion correlates with LV ejection fraction, RV Tei index and with color M-mode velocity. However, since most patients were in NYHA classes I or II, our results can not be extrapolated to the whole population of patients with Chagas dilated cardiomyopathy.

CONFLICT OF INTEREST

The authors declare that there is no conflict of interest.

REFERENCES

1. Cubillos-Garzón LA, Casas JP, Morillo CA, Bautista LE. Congestive heart failure in Latin America: the next epidemic. *Am Heart J* 2004; 147:412-417.
2. Mendez GE, Cowie MR. The epidemiological features of heart failure in developing countries. *Int J Cardiol* 2001; 80:213-219.

3. Prata A. Clinical and epidemiological aspects of Chagas disease. *Lancet Infect Dis* 2001; 1:92-100.
4. Rocha MOC, Ribeiro ALP, Teixeira MM. Clinical management of chronic Chagas' cardiomyopathy. *Front in Bioscience* 2003; 8:44-54.
5. Nunes MCP, Barbosa MM, Rocha MOC. Peculiar aspects of cardiogenic embolism in patients with Chagas' cardiomyopathy: a transthoracic and transesophageal echocardiographic study. *J Am Soc Echocardiogr* 2005; 18:761-767.
6. Perez AA, Ribeiro AL, Barros MV, de Sousa MR, Bittencourt RJ, Machado FS, et al. Value of the radiological study of the thorax for diagnosing left ventricular dysfunction in Chagas' disease. *Arq Bras Cardiol* 2003; 80:208-213.
7. Ferreira, CS. Aspectos radiológicos. In: Cançado JR, Chuster M, editores. *Cardiopatia Chagásica*. Fundação Carlos Chagas M.G. Belo Horizonte; 1985. p. 181-188.
8. Marin-Neto JA, Andrade Z. Por que é usualmente predominante a insuficiência cardíaca direita na doença de Chagas? *Arq Bras Cardiol* 1991; 57:181-183.
9. Acquatella H, Schiller NB, Puigbó JJ, Giordano H, Suárez JA, Casal H, et al. M mode and two- dimensional echocardiography in chronic Chagas' heart disease. *Circulation* 1980; 62:787-799.
10. Barros MV, Rocha MO, Ribeiro AL, Machado FS. Doppler tissue imaging to evaluate early myocardium damage in patients with undetermined form of Chagas' disease and normal echocardiogram. *Echocardiography* 2001; 18:131-136.
11. Barros MV, Machado FS, Ribeiro AL, Rocha MO. Diastolic function in Chagas' disease: an echo and tissue Doppler imaging study. *Eur J Echocardiogr* 2004; 5:182-188.
12. Lang RM, Bierig M, Devereux RB, Flachskampf FA, Foster E, Pellikka PA, et al. Recommendations for chamber quantification: a report from the American Society of Echocardiography's guidelines and Standards committee and the chamber quantification writing group, developed in conjunction with the European Association of Echocardiography, a Branch of the European Society of Cardiology. *J Am Soc Echocardiogr* 2005; 18:1440-1463.
13. Bontrager KL. *Tratado de técnica radiológica e bases anatômicas*. Guanabara Koogan, Rio de Janeiro; 2003.
14. Milne EN, Pistolesi M, Miniati M, Giuntini C. The radiologic distinction of cardiogenic and non cardiogenic edema. *Am J Roentgenol* 1985; 144:879-894.
15. Chinard FP. Estimation of extravascular lung water by indicator dilution techniques. *Circ Res* 1975; 37:137-145.
16. Tei C, Dujardin KS, Hodge DO, Bailey KR, McGoon MD, Tajik AJ, Seward SB. Doppler echocardiographic index for assessment of global right ventricular function. *J Am Soc Echocardiogr* 1996; 9:838-847.
17. Helmcke F, Nanda NC, Hsiung MC, Soto Badey CK, Goyal RG, Gatewood Jr RP. Color Doppler assessment of mitral regurgitation with orthogonal planes. *Circulation* 1987; 75:175-183.
18. Currie PJ, Seward JB, Chan KL, Fyfe DA, Hagler DJ, Mair DD, et al. Continuous wave Doppler determination of right ventricular pressure: a simultaneous Doppler catheterization study in 127 patients. *J Am Coll Cardiol* 1985; 6:750-756.
19. Nagueh SF, Middleton KJ, Kopelen HA, Zoghbi WA, Quinones MA. Doppler tissue imaging: a non-invasive technique for evaluation of left ventricular relaxation and estimation of filling pressures. *J Am Coll Cardiol* 1997; 30:1527-1533.
20. Garcia MJ, Thomas JD, Klein AL. New Doppler echocardiographic applications for the study of diastolic function. *J Am Coll Cardiol* 1998; 32:865-875.
21. Yeo KT, Wu AH, Apple FS, Kroll MH, Christenson RH, Lewandrowski KB, et al. Multicenter evaluation of the Roche NT-proBNP assay and comparison to the Biosite Triage BNP assay. *Clin Chim Acta* 2003; 338:107-115.
22. Rihal CS, Nishimura RA, Hatle LK, Bailey KR, Tajik AJ. Systolic and diastolic dysfunction in patients with clinical diagnosis of dilated cardiomyopathy. Relation to symptoms and prognosis. *Circulation* 1994; 90:2772-2779.
23. Lapu-Bula R, Robert A, De Kock M, D'Hondt AM, Detry JM, Melin JA, et al. Risk stratification in patients with dilated cardiomyopathy: contribution of Doppler-derived left ventricular filling. *Am J Cardiol* 1998; 82:779-785.
24. Hendry A, Hacking L, Langhorne P, Vallance R, MacDonald J. Evaluation of echocardiography in the management of elderly patients with heart failure. *Age Ageing* 1999; 28: 447-450.
25. Ravi K, Kappagoda CT. Left ventricular dysfunction and extravascular fluid in the lung: physiological basis for symptoms. *Indian J Chest Dis Allied Sci* 2008; 50:7-18.
26. Nunes MC, Rocha MO, Ribeiro AL, Colosimo EA, Rezende RA, Carmo GA, et al. Right ventricular dysfunction is an independent predictor of survival in patients with dilated chronic Chagas cardiomyopathy. *Int J Cardiol* 2008; 127: 372-379.
27. Nunes MC, Barbosa MM, Brum VA, Rocha MO. Morphofunctional characteristics of the right ventricle in Chagas'dilated cardiomyopathy. *Int J Cardiol* 2004; 94:79-85.
28. Lewis JF, Webber JD, Sutton LL, Chesoni S, Curry CL. Discordance in degree of right and left ventricular dilation in patients with dilated cardiomyopathy: recognition. *J Am Coll Cardiol* 1993; 21:649-654.
29. Rivas-Gotz C, Manolios M, Thohan V, Nagueh SF. Impact of left ventricular ejection fraction on estimation of left ventricular filling pressures using tissue Doppler and flow propagation velocity. *Am J Cardiol* 2002; 91:780-784.
30. Schwammenthal E, Popescu BA, Popescu AC, Di Segni E, Guetta V, Rath S, et al. Association of left ventricular filling parameters assessed by pulsed wave Doppler and color M-mode Doppler echocardiography with left ventricular pathology, pulmonary congestion, and left ventricular end diastolic pressure. *Am J Cardiol* 2004; 94:488-491.